

REOVIRUS-INDUCED LIVER DISEASE IN SEVERE  
COMBINED IMMUNODEFICIENT (SCID) MICE

A Model for the Study of Viral Infection, Pathogenesis, and Clearance

BY ANNA GEORGE,\* SUSANNE I. KOST,† CAMILLUS L. WITZLEBEN,§  
JOHN J. CEBRA,\* AND DONALD H. RUBIN†

*From the \*Department of Biology, University of Pennsylvania; the  
†Division of Research Medicine, Veterans Administration Medical Center, and  
Department of Microbiology, University of Pennsylvania; and the  
§Department of Pathology, Children's Hospital, Philadelphia, Pennsylvania 19104*

The C.B-17 severe combined immunodeficient (SCID) mouse, described by Bosma et al. (1), has no Peyer's patches (PP) or solitary follicles in the intestinal tract, relatively empty splenic follicles and lymph nodes, and no functional B or T cells. However, it does have a normal complement of APC, macrophages, and NK cells, and therefore constitutes a unique model to investigate viral pathogenesis in the absence of specific immune mechanisms.

In the adult immunocompetent murine host infected orally with reovirus, the virus enters through M cells overlying PP (2). Both reovirus type 1, strain Lang (1/L), and type 3, strain Dearing, cause transient gastrointestinal disease (3, 4), but require high viral inocula ( $10^{10}$  plaque-forming units [PFU]). In studies with adult nude mice, Letvin et al. (5) found no evidence of systemic infection with reovirus inoculated by the oral route, and have suggested that virus replication and spread can be restricted by NK cells and macrophages in the gut.

We have investigated the ability of reovirus to infect adult SCID mice by the natural, oral route. In this host, systemic infection occurs, with reovirus-associated lesions that are restricted to the liver. Virus is not cleared from internal organs and the mice die in 4–6 wk. Protection from disease and death is provided by the adoptive transfer of cells from the PP of congenic mice. Immune donor PP cells can be distinguished from nonimmune cells by their ability to prevent or attenuate viral dissemination and replication by 1 wk after infection.

**Materials and Methods**

*Mice.* Specific pathogen-free C.B-17 SCID breeding pairs were obtained from M. Bosma at the Institute for Cancer Research (Fox Chase, PA) and bred in our germ-free facility. Adult mice were housed in microisolator cages in a pathogen-free facility that is screened regularly

---

This work was supported by Public Health Service grants AI-17997 and AI-23970 from the National Institute of Allergy and Infectious Diseases, and a Merit review grant from the Veterans Administration Medical Center. D. H. R. is supported by a Veterans Administration Career Development Award.

Address correspondence to D. H. Rubin, Department of Research Medicine (151F), Veterans Administration Medical Center, University and Woodland Avenues, Philadelphia, PA 19104. S. I. Kost's present address is the Department of Pediatrics, Children's Hospital, Philadelphia, PA 19104.

for all mouse pathogens, including viruses, and were given autoclaved food and water ad libitum. BALB/c mice were obtained from The Jackson Laboratory (Bar Harbor, ME).

*Viruses.* Reovirus serotype 1/L and type 3, clone 9 (3c9; reference 6), were initially obtained from B. N. Fields (Harvard Medical School, Boston, MA). A third passage stock of virus was purified as described (7), except that cells were disrupted by sonication, instead of homogenizations.

*Antireovirus Antibody and Immunoperoxidate Assay.* The antireovirus antibody used in these experiments has been previously described (3, 8). Viral antigen (Ag) was localized in tissue sections by the biotin-avidin immunoperoxidase technique (3), and sections were examined for Ag-positive cells by light microscopy.

*Immunization and Cell Transfer.* Adult, 8–10-wk-old BALB/c mice were primed intraduodenally with  $3 \times 10^7$  PFU of reovirus types 1/L or 3c9 1 wk before cell transfers, as described (9). Primed mice were kept physically isolated from all other experimental and stock mice. Immune and nonimmune PP cells were isolated as described (10), and the viability of cells was determined by trypan blue exclusion (routinely >98% viable). The required number of cells was transferred intravenously into SCID mice in 0.2 ml of RPMI 1640 (Gibco Laboratories, Grand Island, NY).

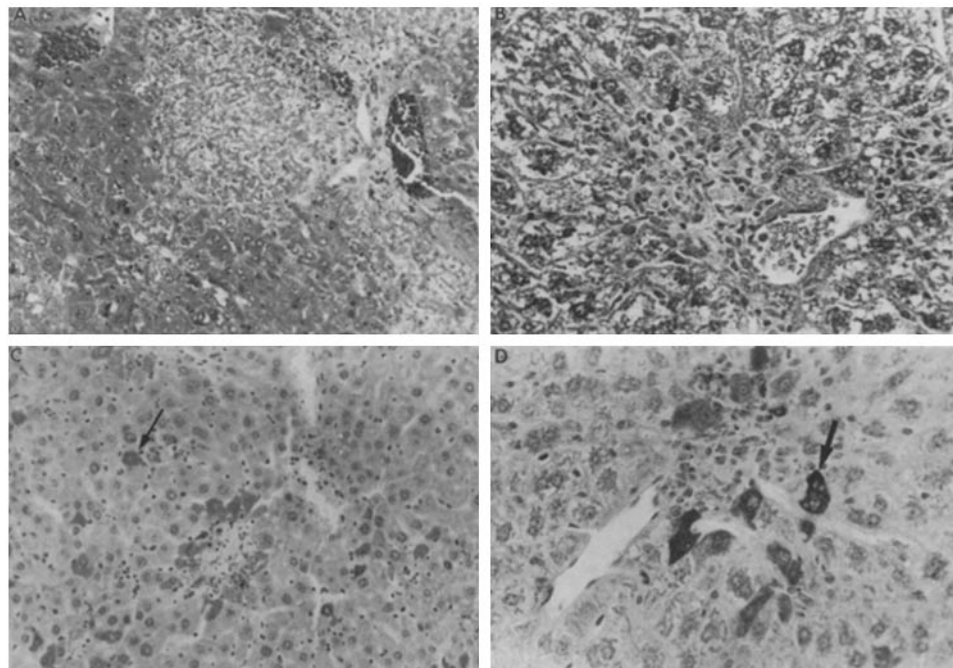
*Collection of Tissues, Titration of Virus, and Histology.* Blood and bile, collected as described (11), were diluted 1:4 in gel saline and stored at  $-70^\circ\text{C}$  until titered. Mice were killed by cervical dislocation, and organs were collected for analysis of virus content and histology. Processing tissues for routine and immunohistochemical analysis was as described (3). The intestinal lumen was flushed with 1.0 ml of gel saline. Portions of intestine, lung, liver, kidney, spleen, and brain were suspended in 1.0 ml of gel saline. All samples were frozen and thawed three times and then disrupted by ultrasound (Ultrasonic 250; Branson Cleaning Equipment Co., Shelton, CT). Virus present in the tissues was assayed on L cell monolayers (3), and the titers were expressed as PFU per milliliter fluid or per gram tissue, as estimated by the method of Lowry et al. (12), using a BSA standard.

## Results and Discussion

*Reovirus Infection Causes Liver Damage and Death in SCID Mice.* C.B-17 SCID mice were infected orally with  $10^5$  or  $10^8$  PFU of reovirus types 1/L or 3c9. Groups of five mice were infected with each serotype of virus at each dose, killed 2 wk after infection, and portions of organs were examined for pathological lesions and virus content. Another group of 17 mice was infected with  $10^8$  PFU of reovirus type 1/L, and tissue specimens from five mice each were obtained 4 and 5 wk after infection for pathology. The remaining mice were dead by 6 wk (data not shown).

With hematoxylin and eosin staining, only the liver showed lesions. The lesions were similar at 2–5 wk after infection with both doses of virus and both serotypes, and the number of lesions increased over time. The lesions ranged from hepatocyte swelling with loss of cytoplasmic basophilia, to frank eosinophilic bodies with pyknotic nuclei. There were also infiltrates of mononuclear and polymorphonuclear cells, and areas of coagulation necrosis rimmed by an inflammatory infiltrate (Fig. 1, A and B). No preferential lobular distribution of the lesions was observed.

The presence of viral Ag was largely restricted to hepatocytes. Antigen-positive hepatocytes were seen at margins of areas of necrosis (Fig. 1, C and D), as well as in areas of inflammation with little or no necrosis, and were associated with inflammatory lesions at 2 wk. However, at 4 wk, positive cells were also found in areas without necrosis or inflammation, and they appeared to correspond, at least in part, to cells with cytoplasmic swelling and loss of basophilia. Scattered sinusoidal lining cells, including Kupffer cells, typically adjacent to areas of necrosis, were also positive. No staining of bile duct epithelium was detected. In organs other than liver,



**FIGURE 1.** Histopathology and immunoperoxidase staining of liver sections from mice infected with  $10^8$  PFU of reovirus type 1/L 4 wk earlier. (A) A large area of necrosis. Surrounding viable hepatocytes have lost cytoplasmic basophilia. Hematoxylin and eosin ( $\times 200$ ). (B) A small area under high magnification (arrow indicates eosinophilic body). (C) A number of immunoperoxidase-positive hepatocytes in the center surrounding a small area of necrosis. Scattered, single immunoperoxidase-positive cells, predominantly hepatocytes, are seen in other areas ( $\times 200$ ). (D) A small area under high magnification. A number of cells, predominantly hepatocytes, are seen at the margins of a small area of coagulation necrosis ( $\times 400$ ). Arrows point to representative reovirus antigen-containing hepatocytes (C and D). Specificity controls for the reagents involved staining tissues from infected mice with the second antibody and avidin-peroxidase, and staining tissues from uninfected mice with all three reagents. The controls were consistently negative (data not shown).

reovirus Ag was detected rarely in crypt epithelial cells and Purkinje cells. The pathological picture was similar in type 1/L- and type 3c9-infected mice (type 3 data not shown).

*Spread of Virus to Distal Organs.* Adult SCID mice were infected by the oral route as above. 2 wk after infection, bile, blood, intestinal segments, and systemic organs were assayed for the presence of infectious virus. The results are shown in Fig. 2. High titers of virus were recovered from samples of all tissues examined, and titers obtained with both serotypes and both virus doses were comparable (high dose data not shown).

The entry of reovirus through intestinal mucosa is known to be mediated by M cells in immunocompetent mice (2). The SCID mouse has no identifiable PP-like structures, but PPs do develop in the mice after syngeneic bone marrow reconstitution (1). Our studies show that reovirus can penetrate the mucosa of SCID mice and spread to distal organs. Therefore, it is possible that M cells are present in the

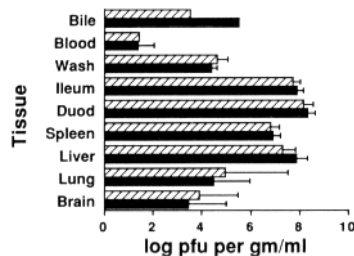


FIGURE 2. Virus titers in tissues of SCID mice 2 wk after infection with  $10^5$  PFU of reovirus type 1/L (solid bars) and type 3c9 (hatched bars) (five mice/group).

gut of SCID mice in the absence of visible PPs. Our results differ from those obtained in immunocompetent mice, where both reovirus types 1 and 3 could penetrate the intestinal mucosa, but only type 1, or reassortant strains carrying the S1 segment of type 1, could spread to distal organs (13).

Although lesions were restricted to the liver, infectious virus was recovered from all tissues examined. Therefore, in other organs, the number of cells with replicating virus may be small. Alternatively, many cells may produce quantities of viral Ag too small to be detected by immunoperoxidase staining. The restriction of virus-induced lesions to the liver may be either due to: (a) Kupffer cell clearance of virus, with continual exposure of hepatocytes to high doses of virus; or (b) the potential of hepatocytes in damaged liver to undergo proliferation and differentiation, which may provide a unique cellular environment that favors viral replication.

*PP Cells from Immunocompetent Congenic Mice Can Prevent Viral Spread and Liver Disease in SCIDS.*  $1.5 \times 10^7$  PP cells from reovirus-immune or naive congenic BALB/c mice were transferred intravenously into SCID mice 48 h before oral challenge with  $10^8$  PFU of the homologous virus. The mice were killed 2 wk later, and tissues were examined for the presence of infectious virus and lesions. No virus was recovered from any tissue of any mouse, and no pathological lesions were observed in any tissue. Nonimmune PP cells were equally effective. These observations suggested the transferred nonimmune cells are primed by the challenge dose of virus and then clear the infection within 2 wk.

A specific protective effect with cells from immune mice was demonstrated when tissues were harvested 1 wk after virus challenge. In contrast to results obtained at 2 wk, PP cells from nonimmune mice could not prevent dissemination of the infection. The containment and resolution of viral infection by immune cells was cell dose dependent, and complete protection was seen with the transfer of  $1.5 \times 10^7$  cells, a number typically obtained from the PP of a single mouse (Fig. 3). Transfer of  $5 \times 10^6$  immune PP cells partially contained the infection, while  $10^6$  cells had little effect.

These experiments show that reovirus causes a lethal infection in adult SCID mice, with obvious pathological changes restricted to the liver. Neither macrophages nor NK cells in the SCID mice can contain or eliminate the infection, and prevent death. Thus, it is likely that clearance of virus and pathological lesions in SCID mice may depend on lymphocytes in the transferred PP population. The SCID mouse infected with reovirus should allow an assessment of the contribution of different components of a specific immune response to viral clearance, and may provide generally

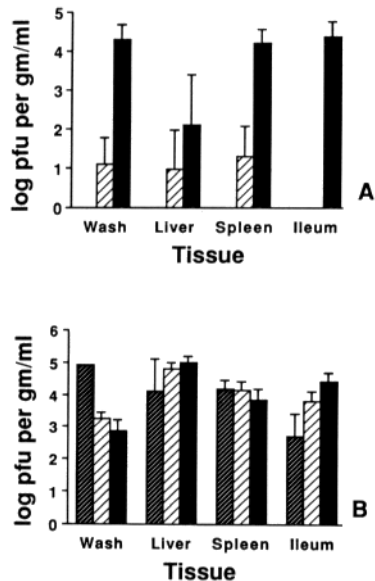


FIGURE 3. Virus titers in tissues of infected SCID mice 1 wk after an oral challenge with reovirus type 1/L. The mice received either  $1.5 \times 10^7$  (dark hatched bars),  $5 \times 10^6$  (light hatched bars), or  $10^6$  (solid bars) PP cells from immune (A) or naive (B) BALB/c mice 48 h before virus challenge (five mice/group).

applicable insights into mechanisms of virus entry and spread, processing of viral antigens in tissues, and clearance of infection in adult immunocompetent mice.

### Summary

Adult severe combined immunodeficient (SCID) mice can be infected by the oral route with reovirus, and a systemic infection can be established. Infectious virus is recovered from all internal organs, and the mice die in 4–6 wk. Chronic, discrete inflammatory lesions appear in the liver of infected mice, and are associated with hepatocytes containing demonstrable levels of viral antigen. The adoptive transfer of Peyer’s patch (PP) cells from congenic mice before infection protects the SCID mice against disease and death. Immune donor PP cells can be distinguished from nonimmune cells by their ability to contain and resolve infection by 1 wk after challenge.

We thank Christine Grico and Allyson Morrison for their excellent technical assistance and Ethel Cebra for preparing and editing this manuscript.

Received for publication 22 May 1989 and in revised form 3 October 1989.

### References

1. Bosma, G. C., R. P. Custer, and M. J. Bosma. 1983. A severe combined immunodeficiency mutation in the mouse. *Nature (Lond.)* 301:527.
2. Wolf, J. L., D. H. Rubin, R. Finberg, R. S. Kauffman, A. H. Sharpe, J. S. Trier, and B. N. Fields. 1981. Intestinal M cells: a pathway for entry of reovirus into the host. *Science (Wash. DC)* 212:471.

3. Rubin, D. H., M. J. Kornstein, and A. O. Anderson. 1985. Reovirus serotype 1 intestinal infection: a novel replicative cycle with ileal disease. *J. Virol.* 53:391.
4. Rubin, D. H., M. A. Eaton, and A. O. Anderson. 1986. Reovirus infection in adult mice: the viral hemagglutinin determines the site of intestinal disease. *Microb. Pathog.* 1:79.
5. Letvin, N. L., R. S. Kauffman, and R. Finberg. 1981. T lymphocyte immunity to reovirus: cellular requirement for generation and role in clearance of primary infections. *J. Immunol.* 127:2334.
6. Hrdy, D., L. Rosen, and B. N. Fields. 1979. Polymorphism of the migration of double stranded RNA genome segments of reovirus isolates from humans, cattle and mice. *J. Virol.* 31:104.
7. Joklik, W. K. 1972. Studies on the effect of chymotrypsin on reoviruses. *Virology.* 49:700.
8. Rubin, D. H. 1987. Reovirus serotype 1 binds to the basolateral membrane of intestinal epithelial cells. *Microb. Pathog.* 3:215.
9. Fuhrman, J. A., and J. J. Cebra. 1981. Special features of the priming process for a secretory IgA response. B cell priming with cholera toxin. *J. Exp. Med.* 153:534.
10. London, S. D., D. H. Rubin, and J. J. Cebra. 1987. Gut mucosal immunization with reovirus serotype 1/L stimulates virus-specific cytotoxic T cell precursors as well as IgA memory cells in Peyer's patches. *J. Exp. Med.* 165:830.
11. Rubin, D. H., M. A. Eaton, and T. Costello. 1986. Reovirus type 1 is secreted into the bile. *J. Virol.* 60:726.
12. Lowry, O. H., N. J. Roseborough, A. L. Farr, and R. J. Randall. 1951. Protein measurement with the folin phenol reagent. *J. Biol. Chem.* 193:265.
13. Kauffman, R. S., J. L. Wolf, R. Finberg, J. S. Trier, and B. N. Fields. 1983. The  $\sigma$  1 protein determines the extent of spread of reovirus from the gastrointestinal tract of mice. *Virology.* 124:403.