


INSIGHTS

IFN γ score-based neoadjuvant immunotherapy for stage III melanoma

Keitaro Fukuda^{1,2} 

In this issue of *JEM*, Reijers et al. (2023. *J. Exp. Med.* <https://doi.org/10.1084/jem.20221952>) demonstrate that pre- and post-treatment IFN γ -related gene expression scores are promising markers for choosing neoadjuvant immunotherapy for stage III melanoma.

Immune checkpoint inhibitors (ICIs), such as anti-PD-1 (nivolumab and pembrolizumab) and anti-CTLA-4 (ipilimumab) antibodies (Abs), have revolutionized the treatment of patients with advanced melanoma. 5-yr overall survival (OS) of patients with melanoma exhibiting distant metastasis (stage IV) treated with anti-PD-1 Ab or anti-PD-1 + anti-CTLA-4 Ab approaches 40 and 50%, respectively (Larkin et al., 2019). However, responses require existing inflammation of the tumor marked by the infiltration of CD8⁺ T cells, a condition known as a “hot” tumor. In contrast, “cold” tumors have minimal CD8⁺ T cell infiltration and exhibit poor response to ICIs (Tumeh et al., 2014). Converting cold tumors into hot tumors has the potential to improve the efficacy of ICI treatments.

Domatinostat is a selective class I histone deacetylase inhibitor that has been reported to increase the expression of tumor neoantigens and MHC class I proteins and synergizes with PD-L1 blockade in murine colon carcinoma models (Bretz et al., 2019). In this issue of *JEM*, Reijers et al. (2023) hypothesized that the addition of domatinostat might improve the adjuvant profiles of cold melanomas. In support of this hypothesis, they showed that both tumor-specific and overall CD8⁺ T cell infiltrations were enhanced by domatinostat; when added to either anti-PD-1 or anti-PD-1 + anti-CTLA-4, this resulted in significantly decreased tumor volumes. RNA

sequencing showed that domatinostat increased expression of genes associated with the IFN γ response, which is consistent with converting cold to hot tumors.

Similar to stage IV melanoma, stage III melanoma with clinically detected nodal metastasis has a poor prognosis due to the high risk of relapse after surgery. Adjuvant nivolumab and pembrolizumab therapy decreased recurrence by ~50% (hazard ratio, 0.54) and improved the OS of stage III melanoma (Eggermont et al., 2018). However, more than 40% of those who received anti-PD-1 as an adjuvant still experienced relapse within 3 yr (Weber et al., 2023). Thus, there is a need to enhance the efficacy of current immunotherapies. Since the addition of ipilimumab to anti-PD-1 improves OS of stage IV melanoma, the Checkmate-915 trial investigated whether adding ipilimumab to nivolumab enhanced its efficacy in the adjuvant setting for stage III. However, no difference in 2-yr relapse-free survival (RFS) was found between the two treatment regimens (Weber et al., 2023), suggesting that adjuvant anti-PD-1 + anti-CTLA-4 is not a promising approach for treating stage III melanoma.

Compared to the adjuvant setting, neoadjuvant anti-PD-1 and anti-CTLA-4 increased tumor-specific CD8⁺ T cell infiltration in preclinical models, due to the presence of abundant tumor antigens at the time of immunotherapy (Liu et al., 2016).



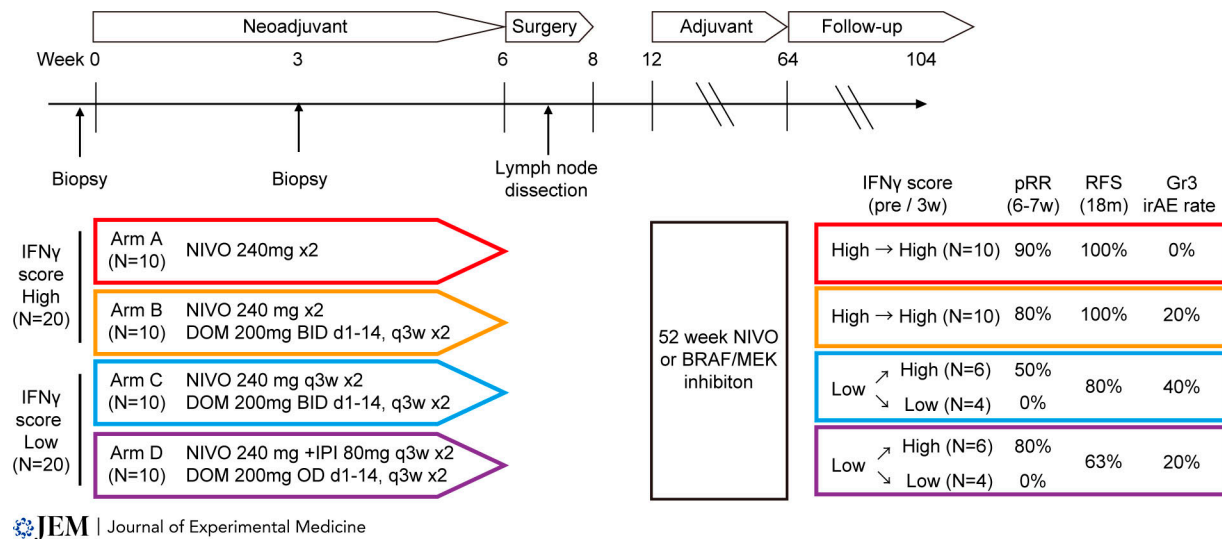
Insights from Keitaro Fukuda.

Based on these results, multiple phase I and II melanoma trials have investigated the efficacy of neoadjuvant immunotherapy for stage III melanoma (Blank et al., 2018; Menzies et al., 2021). These trials revealed that (i) the use of neoadjuvant anti-PD-1 and anti-CTLA-4 increased the abundance of tumor-resident T cell clones in peripheral blood relative to adjuvant anti-PD-1 and anti-CTLA-4; (ii) neoadjuvant anti-PD-1 and anti-CTLA-4 was associated with a high objective response rate (ORR; 73%) and pathological complete remission (pCR) rate

¹Laboratory for Skin Homeostasis, RIKEN Center for Integrative Medical Sciences, Kanagawa, Japan; ²Department of Dermatology, Keio University School of Medicine, Tokyo, Japan.

Keitaro Fukuda: keitaro.fukuda@riken.jp

© 2023 Fukuda. This article is distributed under the terms of an Attribution–Noncommercial–Share Alike–No Mirror Sites license for the first six months after the publication date (see <http://www.rupress.org/terms/>). After six months it is available under a Creative Commons License (Attribution–Noncommercial–Share Alike 4.0 International license, as described at <https://creativecommons.org/licenses/by-nc-sa/4.0/>).



The result of the DONIMI trial. Study schema, clinical efficacy outcomes, and treatment immune-related adverse event (irAE) rates of the DONIMI trial are shown. NIVO, nivolumab; DOM, domatinostat; IPI, ipilimumab.

(45%), although associated toxicity was high (grade 3 adverse events in 73% of patients); (iii) neoadjuvant anti-PD-1 was associated with modest ORR and pCR (both 25%); however, 8% of patients experienced grade 3 toxicity; (iv) pCR, near pCR, or partial pathological response with ICIs was associated with better RFS and OS, as the 2-yr RFS was 96%, compared to 64% in those without a pCR ($P < 0.001$); moreover, the 2-yr OS was 91% for pCR with ICIs versus 82% for those without ($P = 0.050$); and (v) patients with a near-pCR or partial pathological response to ICIs had similar 2-yr RFS as those with a pCR (100 vs. 94%); for those with no pathological response, this rate was 37% ($P < 0.001$). Importantly, it was recently demonstrated that a high IFN γ -related gene expression score (IFN γ score; IFN γ -H) in pretreatment tumor biopsies is associated with improved pathological response and low risk of relapse. Pathological responses occurred in 95 and 59% of patients with IFN γ -H and IFN γ -L tumors, respectively, suggesting that the IFN γ score has significant potential to inform neoadjuvant therapeutic decisions (Rozeaman et al., 2021).

Given this background, Reijers et al. (2023) conducted a phase 1b trial, named DONIMI, to measure the feasibility, safety, and efficacy of different combinations of neoadjuvant nivolumab \pm ipilimumab with domatinostat in patients with stage III melanoma, stratified by baseline tumor biopsy IFN γ score. Patients with high scores were randomized to arm A (two cycles of

nivolumab) or arm B (two cycles of nivolumab + domatinostat twice daily [BID]). Patients with low scores were randomized to arm C (two cycles of nivolumab + domatinostat BID) or arm D (two cycles of nivolumab + ipilimumab + domatinostat once daily).

Unexpectedly, although all patients underwent surgery at the planned time point, the addition of domatinostat to neoadjuvant nivolumab \pm ipilimumab led to frequent grade 3 skin toxicities, particularly at the 200-mg BID dose; therefore, 40, 60, and 20% of patients assigned to arm B, C, and D, respectively, had their domatinostat treatment terminated. Histopathological assessment of the resected surgical specimens revealed a pathologic response rate (PRR; $\leq 50\%$ residual viable tumor) of 90% in arm A, 80% in arm B (both arms included IFN γ -H patients), 30% in arm C, and 40% in arm D (both arms included IFN γ -L patients). IFN γ scores of baseline and on-treatment biopsy samples showed that all arms trended toward higher mean IFN γ scores with treatment; however, the magnitude of the increase was not higher in arm B than in arm A. These results suggest that, in contrast to the results from our mouse model, domatinostat exhibited no benefit to neoadjuvant anti-PD-1 \pm anti-CTLA-4.

Notably, a subset of patients with low baseline scores (arms C and D) exhibited conversion to high scores after 3 wk of treatment, producing a PRR in 50% of patients in arm C and 80% of patients in arm D, whereas patients whose scores remained

low had a 0% PRR. Collectively, these results suggest that while patients with high-high IFN γ scores might obtain long-term benefits from anti-PD-1 monotherapy, patients with low-high scores should continue with a second dose of ipilimumab + nivolumab, and patients with low-low scores need alternative drugs prior to surgery.

While this study supports the importance of pre- and post-treatment tumor IFN γ scores as an early predictor of 18-mo RFS and in prescribing neoadjuvant immunotherapy regimens, the small sample size makes drawing definite conclusions from the data challenging. Furthermore, this trial did not randomize patients who received the combination of ipilimumab and nivolumab. Thus, it only allowed indirect comparisons to historical cohorts with regard to efficacy and the additive effect of domatinostat in those with low baseline scores treated with combination ICIs. To confirm whether IFN γ scores correlate with pathological responses, larger trials testing neoadjuvant anti-PD-1 monotherapy are needed. The phase III NADINA trial (NCT04949113), which tested neoadjuvant nivolumab + ipilimumab compared to adjuvant nivolumab in respectable macroscopic stage III melanoma, could be used to investigate potential correlation. In addition, it is necessary to establish a new treatment that converts cold to hot tumors. Recently, phase II trials of neoadjuvant relatlimab (anti-LAG3) in combination with nivolumab provided a similar pathological

response rate (57% pCR rate and 70% overall PRR) to that of nivolumab + ipilimumab, while it produced no grade 3–4 immune-related adverse events. Pathological responses were associated with increased immune cell infiltration at baseline and decreased M2 macrophages during treatment (Amaria et al., 2022). Thus, a candidate neoadjuvant immunotherapy regimen for low–low IFN γ score stage III melanoma may be the combination of relatlimab, nivolumab, and ipilimumab. This potential combination requires further study but constitutes a promising potential treatment regimen.

Acknowledgments

This work was supported by a Grant-in-Aid for Scientific Research (C) from the Ministry of Education, Culture, Sports, Science, and Technology—Japan (grant 21K08356 to K. Fukuda).

Disclosures: The author declares no competing financial interests.

References

- Amaria, R.N., et al. 2022. *Nature*. <https://doi.org/10.1038/s41586-022-05368-8>
- Blank, C.U., et al. 2018. *Nat. Med.* <https://doi.org/10.1038/s41591-018-0198-0>

- Bretz, A.C., et al. 2019. *J. Immunother. Cancer*. <https://doi.org/10.1186/s40425-019-0745-3>
- Eggermont, A.M.M., et al. 2018. *N. Engl. J. Med.* <https://doi.org/10.1056/NEJMoal802357>
- Larkin, J., et al. 2019. *N. Engl. J. Med.* <https://doi.org/10.1056/NEJMoal910836>
- Liu, J., et al. 2016. *Cancer Discov.* <https://doi.org/10.1158/2159-8290.CD-16-0577>
- Menzies, A.M., et al. 2021. *Nat. Med.* <https://doi.org/10.1038/s41591-020-01188-3>
- Reijers, R.P.M., et al. 2023. *J. Exp. Med.* <https://doi.org/10.1084/jem.20221952>
- Rozeman, E.A., et al. 2021. *Nat. Med.* <https://doi.org/10.1038/s41591-020-01211-7>
- Tumeh, P.C., et al. 2014. *Nature*. <https://doi.org/10.1038/nature13954>
- Weber, J.S., et al. 2023. *J. Clin. Oncol.* <https://doi.org/10.1200/jco.22.00533>