

THE EFFECT OF HYPERTROPHIC CARTILAGE ON BONE MARROW GROWTH*

BY CHARLES HUGGINS, M.D., AND KENNETH McLANE SMITH, M.D.

(From the Department of Surgery, The University of Chicago, Chicago)

PLATES 1 AND 2

(Received for publication, September 27, 1937)

Following intravenous injection it was found that thorium dioxide became firmly fixed locally in the bone marrow and in the young rabbit subsequent areas of marrow growth were thorium-free and hence could be recognized. The way of growth of bone marrow in the cartilage bones is the subject of this communication. There have been many studies of histogenesis in marrow but the larger motif of growth has not been described previously.

Much data suggest that bone marrow activity is not scattered at random among the fat-containing cells within bone but assumes certain patterns. The elongated nature of the bones of the extremities with accompanying changes in the physicochemical system of this outlying tissue provides a natural distortion of the forces at work on bone marrow in general, simplifying the correlation of form with causality. This natural distortion frequently is as high grade as is found satisfactory in a planned experiment. The length of the marrow of the tapering extremity thus furnishes more satisfactory material for functional analysis than is present in the relatively short squat bones of the body trunk.

One of the marrow patterns of adult homeothermous animals is the accumulation of fatty marrow in the outlying bones with active red marrow in the central bones. Evidence has been presented (1-3) relating this difference to a thermal gradient in the extremities.

Superimposed on this simple proximal-distal relationship of red and yellow marrow of the adult is another pattern, the accumulation of red marrow at the growing region of the cartilage plates in the long

* This investigation was aided by a grant from the Fenger Memorial Fund.

bones of the adolescent animal. In the rat whose epiphyses never close, it was found (2, 3) that when the temperature of the outlying bones of the tail was elevated to the deep body level, red marrow returned to the previously fatty metaphyseal regions.

In the present experiments it was found that colloidal thorium dioxide injected intravenously remained fixed in the reticulo-endothelial cells, without causing noticeable effect on the animal. The tenacity with which it is held locally and the ease of identification of this substance enabled recognition of new areas of marrow growth, so that the growth pattern stood out plainly.

Colloidal thorium dioxide injected intravenously was found to accumulate in the reticulo-endothelial system by Oka (4) and Radt (5). Following relatively large doses, the distribution of the metal in the macrophages of bone marrow makes this structure visible by x-ray examination of the living rabbit, where thorium is concentrated (13).

Materials and Methods

37 rabbits, mostly young, were injected intravenously with an electronegative thorium dioxide sol (thorotrast¹) containing approximately 25 per cent by weight of ThO₂ in submicroscopic particulate form. The dosage administered was relatively large, 4 to 6 cc. at 2 day intervals until each rabbit had received 10 to 15 cc. per kilo; no toxic effects were observed with these amounts but injections of 8 cc. proved fatal on 2 occasions. Before and after injection the venous blood was studied repeatedly from the standpoint of erythrocyte, leucocyte, and hemoglobin content. The cells were counted by the standard pipette and counting chamber method and the oxygen capacity of the blood was determined by the Stadie-Wu method (14). X-rays were made of the extremities each week. Where there are many macrophages, the marrow is clearly visible to x-ray after 12 cc. per kilo have been injected. At intervals of 1 to 118 days the rabbits were killed; following 10 per cent formalin fixation and decalcification with 5 per cent nitric acid, x-ray films were again made. Since thorium dioxide is insoluble in this acid a shadow of the metal as it is deposited in the marrow cells was obtained. Subsequently histological sections were made with a paraffin technique. Unna-Pappenheim plasma cell stain was useful in identifying the thorium dioxide in the tissues.

In 6 rabbits, 1 to 2 months of age, under ether anesthesia, small bits of sterile chromium steel wire were inserted into the bone marrow of lower femora and upper

¹ We are indebted to the manufacturers, the Heyden Chemical Company, for this material.

tibiae through a hypodermic needle (No. 18 gauge) introduced by a boring motion of the wrist. The lack of resistance to the needle after traversing the rigid bone identifies the marrow cavity.

To determine how firmly thorium dioxide is fixed locally after coming to rest in the macrophages, drastic disturbances of the bone marrow were induced in 3 series of rabbits after thorium injections had been completed. In 6 rabbits plethora was produced as in the experiments of Robertson (6) except that 20 to 40 cc. of blood were injected daily for 12 to 20 days. In a similar series, anemia was produced by cardiac puncture with removal of sufficient blood to keep the oxygen capacity less than 9 volumes per cent, and maintained for 3 weeks. 4 other rabbits were kept anemic at a temperature of 35°C. in an incubator for 3 weeks.

RESULTS

Effect on the Blood Cells.—There was no significant effect on the cells of the peripheral blood following administration of these relatively large amounts of thorium dioxide. In the series of 37 rabbits, the average hemoglobin values before and after injection were 16.2 and 16.0 volumes per cent oxygen capacity, respectively. The average red cells and white cells of the blood before injection were 5,670,000 and 8660, respectively, and after injection these values were found to be 5,650,000 and 8500 per c. mm.

Intensity of Fixation of Thorium Dioxide in Macrophages.—In the plethora experiments, readings for hematocrit ranged from 58 to 70, for red cells 8,270,000 to 9,650,000, and for oxygen capacity in volumes per cent 23.4 to 26.2. The anemic rabbits were kept at an oxygen capacity level less than 9 volumes per cent.

Sufficient growth of bone marrow and bone occurred during these periods of hemoglobin disturbance to enable one to recognize clearly the newly formed marrow. Where it was present no thorium dioxide was found in the macrophages. It was concluded that this metal was exceedingly firmly held locally after the original cellular ingestion.

The Normal Growth Pattern of Bone Marrow.—This is shown in Figs. 1 to 5. Longitudinal growth of the reticulo-endothelial system occurs at the epiphyseal cartilage plate, and in the zones of hypertrophic cartilage in the epiphyses. Longitudinal growth is chiefly if not entirely at the ends of the bone; the amount of interstitial growth is apparently much less. The histological preparations (Figs. 10 to 12) entirely supported this opinion. The region of the cartilage plate

in rabbits soon after the injections had been completed contained many thorium-laden cells, but where weeks or months had elapsed since the last injection, this area was entirely devoid of the metal.

Examination of the epiphyseal region 1 or 2 days after completing the thorium injections elucidates the mechanism of marrow growth. It was found that each cartilage column was faced at the aspect bordering on the marrow with a thorium-laden macrophage (Fig. 10).

From those experiments where bits of chromium wire were inserted, followed by thorium dioxide injections, a similar opinion was derived. The wires served as fixed points in the bone marrow and the epiphyseal plates grew away from these points and new thorium-free marrow was formed in the interval.

Width growth is likewise visible in similar x-ray and histologic studies of the long bones. At the periphery, the marrow was found packed with thorium-laden macrophages following recent injection; in experiments of longer duration since injection, the thorium-containing older marrow occupied a more central position in the bone and was surrounded by a rim of thorium-free marrow.

The Normal Growth Pattern of Liver and Spleen.—These organs like the bone marrow have a sinusoidal circulation and are rich in macrophages. X-ray and histological studies of liver and spleen show that growth here is interstitial and not polarized as in the marrow (Fig. 7).

DISCUSSION

It is now possible to correlate the observations made on normal marrow growth with some previous observations.

It was shown (2) that when a graft of avascular precartilage was transplanted to any region of the donor it became vascularized with endothelium having a phagocytic character. The primitive precartilage of the tail of a newborn rat transplanted to various tissues, for example the subcutaneous tissue of the abdomen, the peritoneal cavity, or the pleura, became invaded with blood vessels lined by macrophages instead of common non-phagocytic endothelium. The nature of the graft determined that any vessel entering would develop reticulo-endothelial system properties; this character is not inherent in the vessel as such but is conditioned by the graft.

Amid the welter of theories as to the resorption of cartilage at the epiphysis as it is replaced by bone, the work of Ranvier stands out. This investigator (9) found that blood vessels branch among the cartilage columns of the epiphysis, bend there in loop form with the apex of the loop touching directly on a cartilage cell capsule which soon thereafter disappears. It was unknown at the time of Ranvier's work that the lining of the marrow blood vessels is phagocytic.

Shipley and Macklin (7) injected trypan blue into the peritoneal cavity of rabbits, kittens, and chicks, killing the animal 1 to 4 days later. They found that only the reticulo-endothelial cells of the marrow were stained and stated: "At the margin between cartilage and bone at the epiphysis there was a narrow zone where these macrophages were very numerous and a distinct line of them could be made out along the edge of the cartilage to which they were apparently closely applied." Similar findings have been reported with colloidal carbon (8). The deposition of thorium dioxide in corresponding cells in our material confirms this observation as to the phagocytic nature of the marrow cells in juxtaposition to the epiphyseal cartilage growth zone.

In addition to the phagocytic property of sinusoidal endothelium, this substance in the bone marrow through much evidence is believed to be of direct importance in the fabrication of blood-forming tissue (10) and is even regarded as the mother tissue of the formed elements of the blood (11).

The evidence presented in this paper together with that just cited permits deduction of an hypothesis of marrow growth. Any vessel entering a region of hypertrophic cartilage acquires a phagocytic lining. These phagocytic cells accumulate at the regions where cartilage is disappearing to be replaced by bone and their usual phagocytic character infers the likelihood that they participate in cartilage removal. These cells then or their descendants are thus placed in the region where marrow is forming to which they contribute. In addition to the function of cartilage removal, these cells are in a position to form marrow. The epiphyseal plates in this manner polarize length growth of bone marrow. Growth of liver and spleen on the other hand was found to be interstitial.

Growth in width of the marrow has been shown in these experiments to be essentially a peripheral effect occurring in the region where bone is being removed to enlarge the marrow cavity. In view of the observations of Beard and Rous (12) of the tendency of liver macrophages in tissue culture to scatter and climb, it is possible that peripheral growth is due to some such effect occurring when the marrow cavity is enlarged.

SUMMARY

Intravenous injections of colloidal thorium dioxide were made in rabbits and moderate amounts caused no significant changes in the cellular elements of venous blood. Thorium dioxide was held locally with great tenacity in the cells of the reticulo-endothelial system in the bone marrow and showed little tendency to migrate despite drastic stimuli to the marrow in the form of anemia and plethora.

In recently injected rabbits, thorium-laden macrophages abutted each cartilage column in the direction of growth where the cartilage was being removed. In marrow which had formed subsequent to injection the macrophages were thorium-free, allowing recognition of the new tissue by x-ray and histological techniques as clear zones. The growth pattern of marrow could be detected in this way.

The bone marrow increases in length principally in the region of hypertrophic cartilage at the metaphyses and it is evident that the increase is facilitated by the presence of macrophages whose primary function is the resolution of the wasted hypertrophic cartilage cells. Growth in thickness of bone marrow occurs at its circumference. In contrast to the zonal growth of bone marrow, growth of the reticulo-endothelial system in liver and spleen is chiefly interstitial.

BIBLIOGRAPHY

1. Huggins, C., Blocksom, B. H., Jr., and Noonan, W. J., *Am. J. Physiol.*, 1936, **115**, 395.
2. Huggins, C., and Blocksom, B. H., Jr., *J. Exp. Med.*, 1936, **64**, 253.
3. Huggins, C., and Noonan, W. J., *J. Exp. Med.*, 1936, **64**, 275.
4. Oka, M., *Fortschr. Geb. Röntgenstrahlen*, 1929, **40**, 497.
5. Jaffe, R., *Fortschr. Geb. Röntgenstrahlen*, 1929, **40**, 692.
6. Robertson, O. H., *J. Exp. Med.*, 1917, **26**, 221.

7. Shipley, P. G., and Macklin, C. C., *Am. J. Physiol.*, 1916, **42**, 117.
8. Wislocki, G. B., *Bull. Johns Hopkins Hosp.*, 1921, **32**, 132.
9. Ranvier, L., *Technisches Lehrbuch der Histologie*, translated by Nicati, W., and von Wyss, H., Leipsic, F. C. W. Vogel, 1877, 411.
10. Sabin, F. R., *Physiol. Rev.*, 1928, **8**, 191.
11. Wiseman, B. K., *J. Am. Med. Assn.*, 1934, **103**, 1524.
12. Beard, J. W., and Rous, P., *J. Exp. Med.*, 1934, **59**, 593.
13. Kadrnka, S., and Rossier, J., *Acta Radiol.*, 1931, **12**, 369.
14. Wu, H., *J. Biochem.*, Japan, 1922, **2**, 173.

EXPLANATION OF PLATES

PLATE 1

Figs. 1 to 5. X-rays of lower femur of growing rabbits at intervals after injection of thorotrast intravenously. The bones were decalcified in 5 per cent nitric acid before radiography. The clear zone between the epiphysis and marrow of the diaphysis represents the growth of marrow at the epiphyseal cartilage.

FIG. 1. X-ray made 1 day following injections totaling 32 cc.

FIG. 2. X-ray made 42 days following injections totaling 28 cc.

FIG. 3. There were two series of injections, the first 41 days and the second 20 days before this x-ray was made. Two thorium levels may be seen.

FIG. 4. X-ray made 97 days following injections totaling 33 cc.

FIG. 5. X-rays made 108 days following injections totaling 26 cc.

FIG. 6. Similar to Figs. 1 to 5 except that the rabbit was adult. This x-ray was made 36 days after injection of 38 cc.

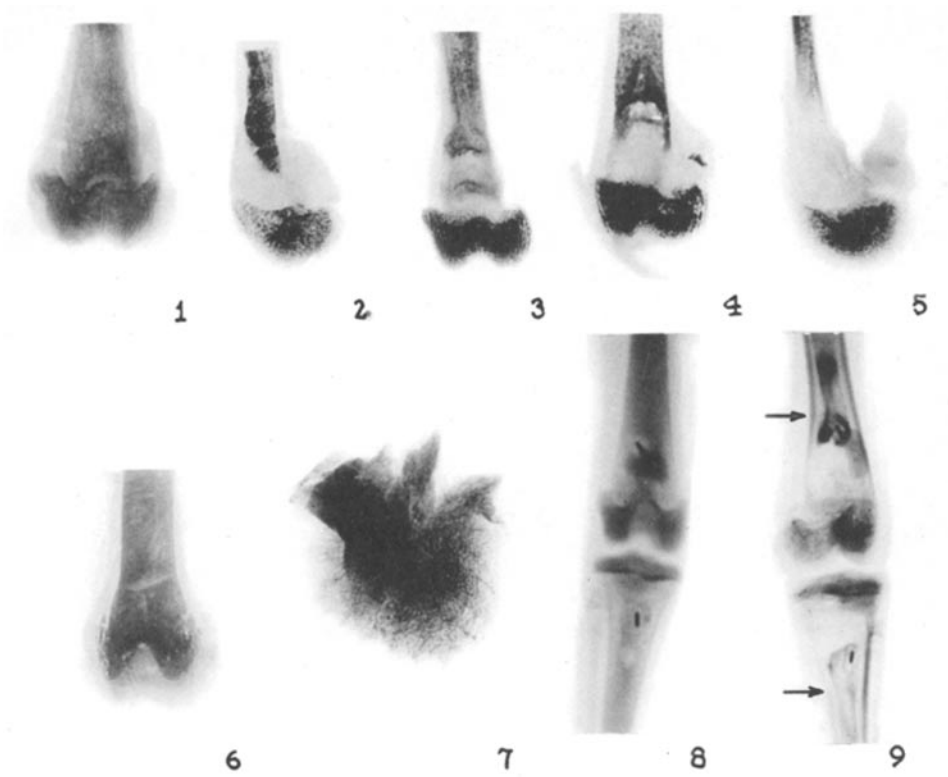
FIG. 7. A lobe of the liver of the same animal as in Fig. 5. Thorium reaches to the liver edge and there is no clear zone of new growth.

FIG. 8. Small pieces of chromium steel wire (densest bars) were placed in tibia and femur of this 32 day old rabbit which was then injected with 8 cc. thorotrast intravenously. This x-ray was made on completion of injection, 9 days after operation. This and Fig. 9 are x-rays made on the living animal.

FIG. 9. Same as Fig. 8, 85 days later. The epiphyses have grown away from the bits of wire and the thorium in the diaphysis, leaving a clear zone of new marrow growth. At the periphery the arrows point to the clear zone where growth in width has taken place.

Figs. 10 to 12. These illustrations are photographs of sections stained lightly with Unna-Pappenheim plasma cell stain.

FIG. 10. The lower femoral epiphyseal cartilage 1 day following the injection of 22 cc. of thorotrast. Each hypertrophic cartilage cell bordering on the marrow cavity is faced with a macrophage containing particulate thorium dioxide. $\times 172$.

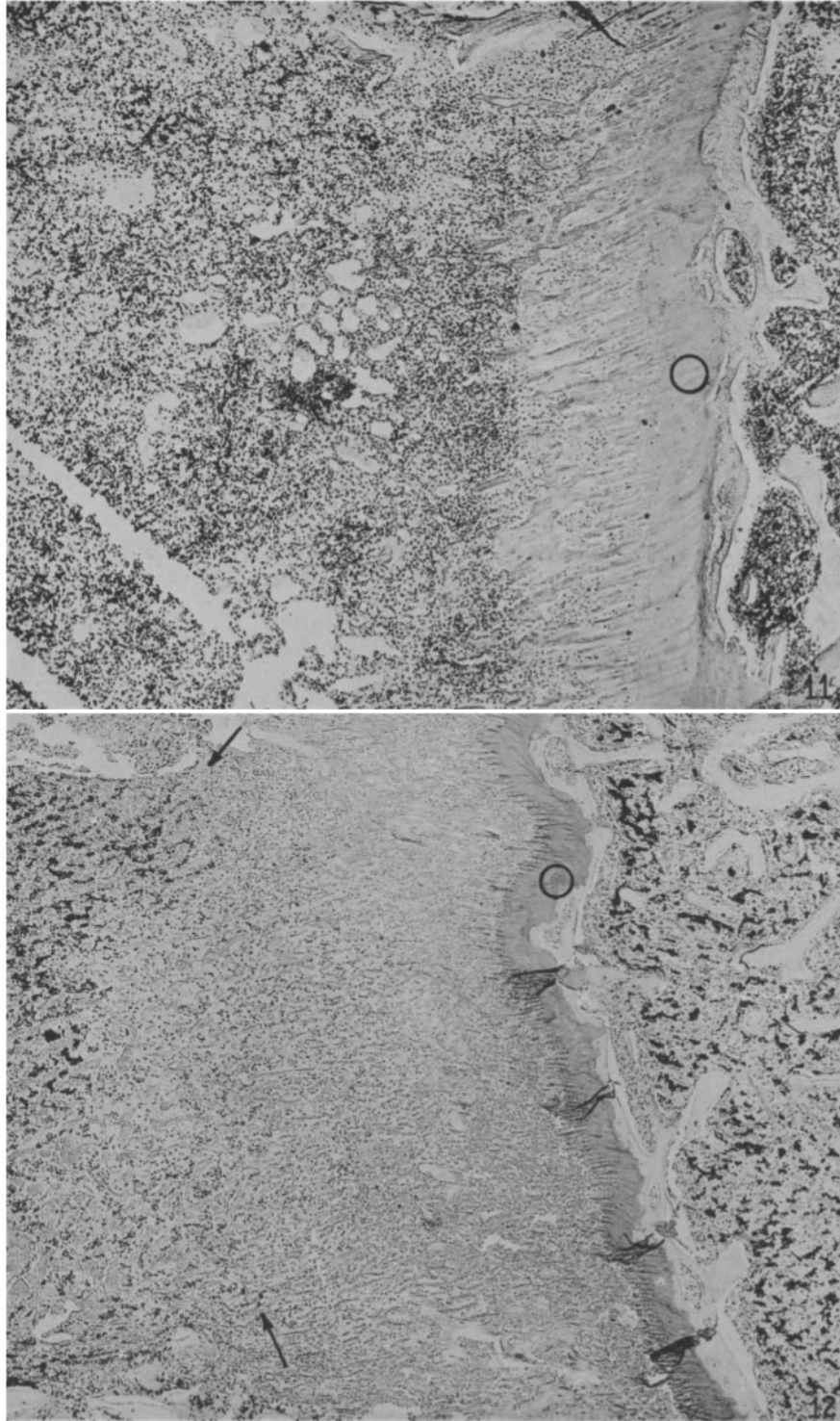


(Huggins and Smith: Hypertrophic cartilage and bone marrow growth)

PLATE 2

FIG. 11. The lower femoral epiphysis 1 day following injection of 27 cc. of thorotrast. The dense black thorium dioxide clumps reach the epiphyseal cartilage (○). × 25.

FIG. 12. Same as Fig 11 in a litter mate 36 days following completion of injection of 26.2 cc. of thorotrast. At the left arrows point to the lower limit of the thorium, the epiphyseal cartilage (○) is at right of center and the epiphysis marrow is farther right. The thorium-free zone of new marrow growth lies between the arrows and the epiphyseal cartilage (○). × 25.



(Huggins and Smith: Hypertrophic cartilage and bone marrow growth)