

STUDIES ON EXPERIMENTAL HYPERTENSION

XIX. THE PRODUCTION OF PERSISTENT HYPERTENSION IN SHEEP AND GOATS*

BY HARRY GOLDBLATT, M.D., JOSEPH R. KAHN, M.D., AND
HARVEY A. LEWIS, M.D.

(From the Institute of Pathology, Western Reserve University, Cleveland)

(Received for publication, December 7, 1942)

For the study of experimental renal hypertension, dogs and the small herbivorous laboratory animals have been used, but the latter have some obvious disadvantages. The determination of blood pressure is usually more difficult and less reliable and the amount of blood that can be obtained for chemical studies is small. It was considered of interest, therefore, to determine whether persistent hypertension could be induced in large herbivorous animals that can be handled in a laboratory. One special advantage of all large animals is the greater supply of blood which becomes available for the study of the humoral mechanism involved in the pathogenesis of this type of hypertension (9). For the small or large carnivorous type of animal, dogs are excellent and were the first animals used (1). For the production of experimental hypertension in large herbivorous animals, sheep and goats were chosen.

Persistent hypertension as the result of permanent partial constriction of the main renal arteries by means of silver clamps was produced first in dogs (1). Later, hypertension was also produced by the same method and with the same or other devices in monkeys (2), rabbits (3), and rats (4). In all animals, the method consisted essentially in partial constriction of the main renal artery and the consequent disturbance of the intrarenal hemodynamics. To effect this in the monkey, a small silver clamp like that for the dog was used (2). For the rabbit, a still smaller clamp or a simple silver clip was employed (3). Another device to constrict the main renal artery in rabbits, which can also be used for other small animals, is to tie a thread around the main renal artery and a rod of round metal laid alongside of it. When the rod is removed, the degree of constriction of the artery which results depends upon the diameter of the rod used (5). This method can also be used in the young growing animal, without actual constriction of the artery by the thread. As the animal grows, the restriction of arterial blood to the kidney increases because the thread does not give. The objection to this method is that renal excretory insufficiency with fatal uremia is a frequent complication (5). For the rat, a small silver clip (4) or a silk thread (6) has been employed. If the initial constriction is inadequate, so that hypertension does not develop, or if the natural and acquired accessory circulation

* This study was supported by the Beaumont Trust (L. D. Beaumont) and by grants-in-aid from the Josiah Macy, Jr., Foundation, the John and Mary Markle Foundation, and a group of Cleveland donors.

to the kidneys becomes so rich that the hypertension begins to disappear, another operation may be performed and the constriction of one or both main renal arteries may be increased. By gradually increasing the constriction, the main renal arteries of both kidneys may finally be occluded, without inducing renal excretory insufficiency and uremia, because of the development of adequate accessory circulation to the kidney along the ureter and into the cortex from various sources around the kidney. To decrease the accessory circulation to the kidney, either before constriction of the renal artery, or later, an organic membrane (any type of "fishskin" condom) is wrapped around the kidney, with special care to avoid constriction of the structures composing the renal pedicle (7). This type of membrane does not produce a thick

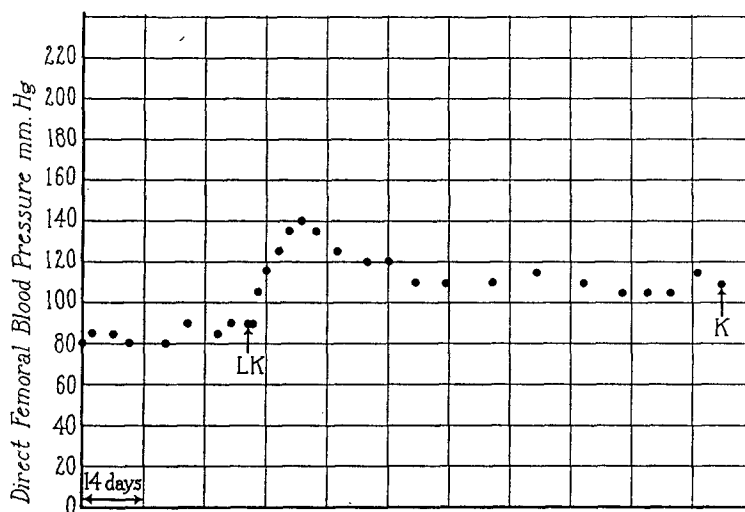


FIG. 1. Sheep 4, female, age 6 months at beginning of control period. LK, left main renal artery moderately constricted. The blood pressure remained significantly elevated for 4 months at which time the animal was sacrificed (K).

hull of scar tissue around the kidney or renal pedicle, which frequently occurs when a kidney is enclosed in a silk or cellophane membrane (8). Distortion and destruction of kidney substance and development of hydronephrosis, with consequent fatal uremia, frequently caused by the silk or cellophane membrane (8), are only exceptional effects of the fishskin condom.

EXPERIMENTS

The full grown animals were about 1 year old at the beginning of the control period. Two sheep, born in this Institute, were 6 months old when the first operation on them was performed. Mean arterial pressure was determined by the direct method, which consisted of the insertion into the femoral artery of a 21 gauge needle on the end of the barrel of a 1 cc. tuberculin syringe which was connected with a mercury manometer by means of rubber tubing filled with anticoagulant fluid (4 per cent sodium citrate).

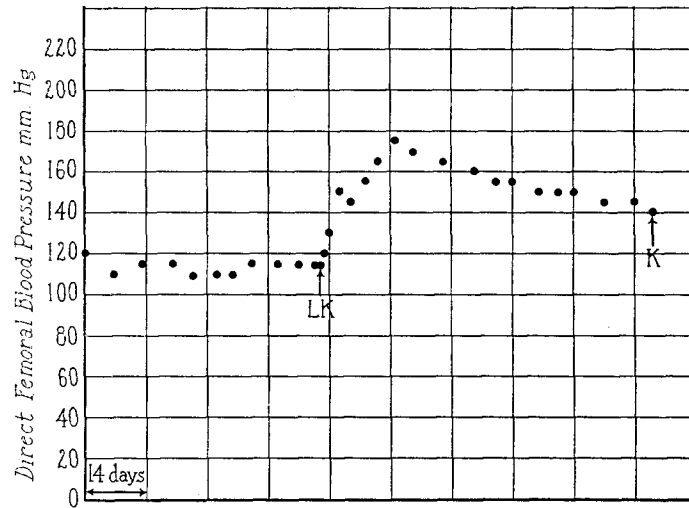


FIG. 2. Goat 4, female, age about 1 year. LK, left main renal artery constricted. The blood pressure remained elevated for nearly 3 months. The animal became partially paralyzed, for some unexplained reason, and was sacrificed (K).

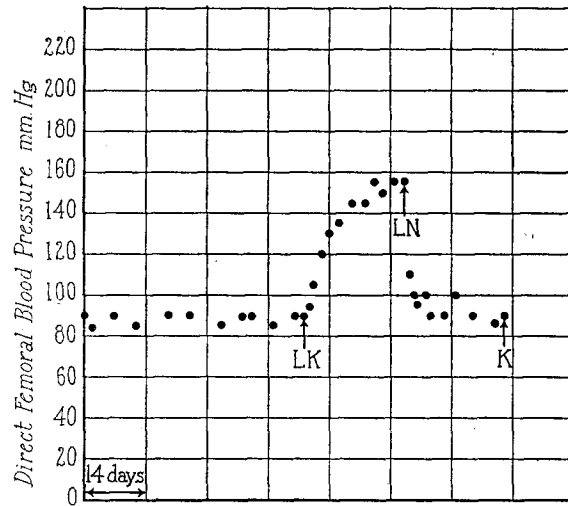


FIG. 3. Sheep 5, female, age 6 months. LK, left main renal artery constricted. LN, at the height of the elevation of blood pressure which followed the left kidney was excised. Within 48 hours the blood pressure had returned to normal and it remained normal until the animal was sacrificed (K).

Control Period.—Sheep are unusually placid animals, even when kept under laboratory conditions. During the control period their direct mean femoral blood pressure was remarkably uniform (Figs. 1, 3, 5, and 6). Although goats

are much more excitable and less tractable than sheep, yet their blood pressure varied little from week to week during the control period, but their normal blood pressure was higher than in the sheep (Figs. 2, 4, 7, and 8).

The Effect on the Blood Pressure of Constriction of the Main Artery of One Kidney

As in dogs, and other animals (1-4), so also in both sheep and goats, constriction of the main artery of one kidney resulted in a prompt rise of blood pressure which persisted for a variable period. As in the dog, the rise usually began within 24 or 48 hours. The only significant difference noted was that in both sheep and goats, as the result of this procedure, the blood pressure tended to remain elevated for a longer period than is usual in the dog with only one main renal artery constricted. Figs. 1, 2, 4, and 5 illustrate this fact. In goat 3 (Fig. 4), considerable hypertension was present 6 months after the constriction of only one main renal artery.

The Effect on the Blood Pressure of Excision of the Kidney with Renal Artery Constricted

As in other animals with hypertension due to constriction of the main artery of one kidney, the excision of this kidney, when the other kidney was normal, invariably resulted in a return of the blood pressure to the normal level, usually within 24 hours, (Figs. 3, 4, and 7) and it persisted at this level until the other renal artery was constricted (Figs. 4 and 7).

The Effect on Blood Pressure of Constriction of One Main Renal Artery with Excision of the Contralateral Kidney

It has been shown that in dogs, at the height of the elevation of blood pressure due to constriction of the main artery of one kidney, excision of the contralateral normal kidney results in persistence of the hypertension (10). Similarly, after constriction of one main renal artery, when the blood pressure has returned almost to normal, the excision of the contralateral normal kidney is followed by a re-elevation of the blood pressure, which persists. Fig. 5 is an illustration of the latter in a sheep.

The Effect on Blood Pressure of Constriction of Both Main Renal Arteries

In dogs, moderate constriction of both main renal arteries, with an interval of weeks between the two operations, results in persistent hypertension (1). In order to make the hypertension persist, in some of the animals, it has been found necessary later to increase the constriction of both main renal arteries and even to surround one or both kidneys with an organic membrane to eliminate the accessory circulation to the kidneys which often develops after constriction of the main renal artery. Fig. 6 illustrates the effect of moderate constriction of both main renal arteries in a sheep. The effect on the blood

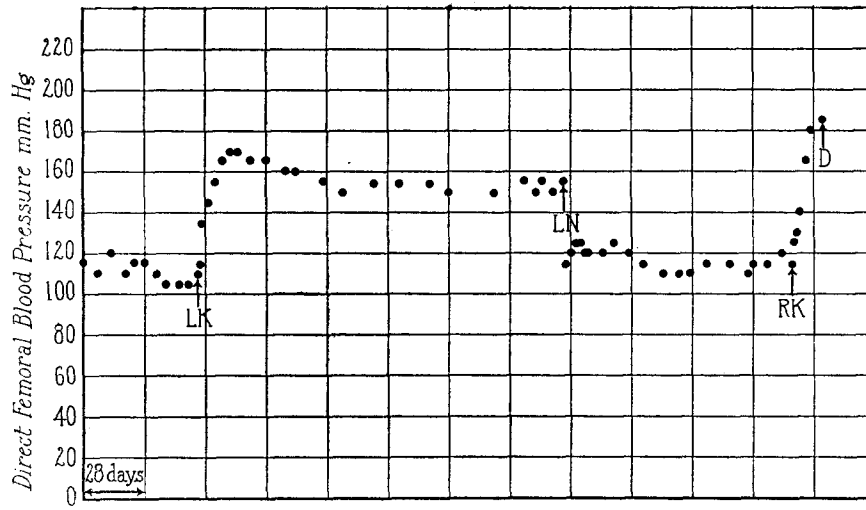


FIG. 4. Goat 3, female, age about 1 year. LK, left main renal artery was moderately constricted. The blood pressure remained considerably elevated for 6 months. LN, the left kidney was excised and within 24 hours the blood pressure returned to normal and remained at this level. RK, the right main renal artery was greatly constricted. The blood pressure became re-elevated but the animal developed uremia and died (D). Terminally B.U.N. (blood urea nitrogen) 134 mg., Cr. 5.8 mg., CO_2 combining power 40.5 volumes per 100 cc.

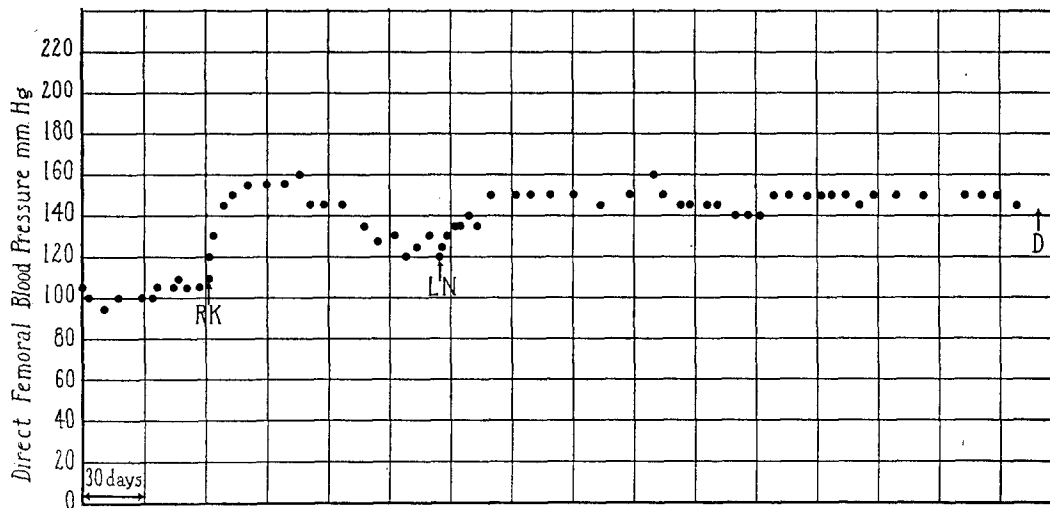


FIG. 5. Sheep 3, female, age about 1 year. RK, right main renal artery moderately constricted. The blood pressure became considerably elevated but after 4 months it had almost returned to normal. LN, excision of the contralateral normal kidney resulted in a significant re-elevation of blood pressure which persisted. D, the animal developed pneumonia and died.

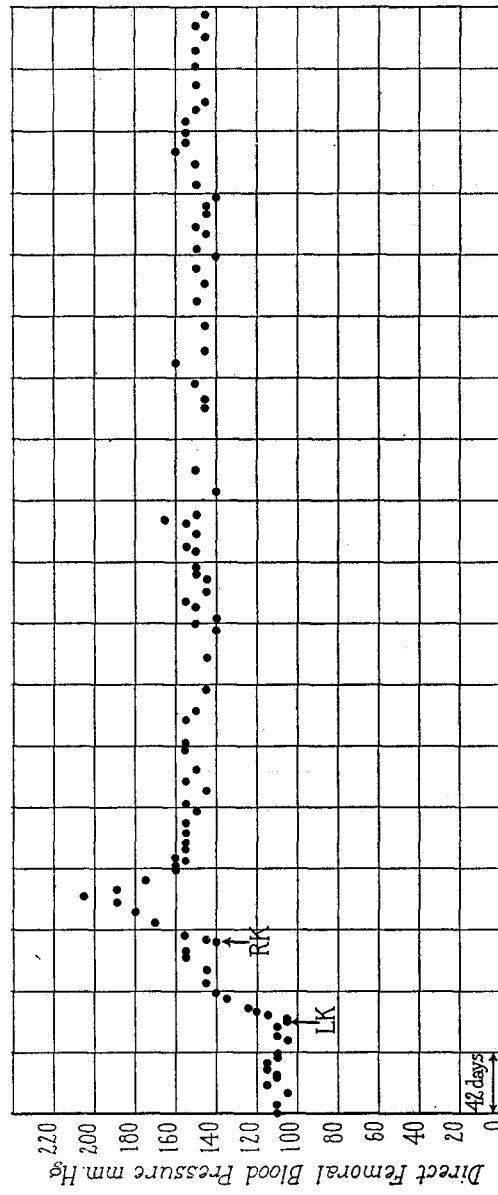


FIG. 6. Sheep 1, female, age about 1 year. LK, left main renal artery moderately constricted. The blood pressure became significantly elevated. RK, right main renal artery moderately constricted. The blood pressure rose higher and then settled down to a moderate elevation which has persisted for nearly 2 years. The animal is still living.

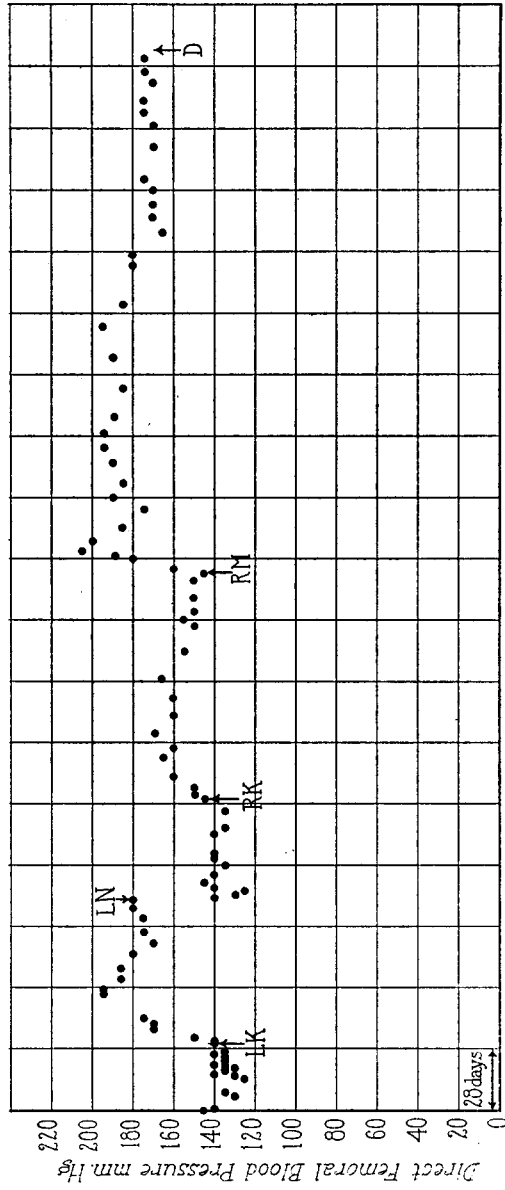


FIG. 7. Goat 2, female, age about 1 year. LK, left main renal artery moderately constricted. LN, at the height of the elevation of blood pressure which followed, the left kidney was excised. RK, the right main renal artery was slightly constricted. The blood pressure became slightly elevated and tended to return to normal. RM, the right kidney was enclosed in a fishskin condom. The blood pressure became re-elevated and remained elevated for 8 months. There was no significant increase of nitrogenous products in the blood at any time during this period. D, found dead. Pneumonia.

pressure of enclosing in a fishskin condom the kidney with main renal artery constricted is well shown in Fig. 7. The blood pressure became re-elevated and remained at a high level for 8 months.

In dogs, great initial constriction of both main renal arteries often results in the development of hypertension accompanied by uremia which usually proves rapidly fatal. Fig. 8 is an illustration of this effect in the goat and shows that the malignant phase resulted from the excessive constriction of both main renal arteries.

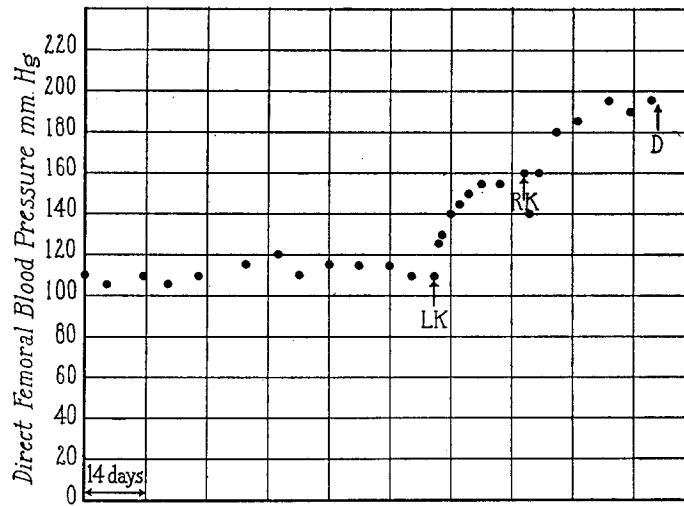


FIG. 8. Goat 1, female, about 1 year old. LK, left main renal artery greatly constricted. RK, right main renal artery greatly constricted. The blood pressure became greatly elevated but the animal developed progressive uremia. Terminally B.U.N. 82.3 mg., Cr. 4.5 mg., CO_2 combining power 44.0 volumes per 100 cc. D, died in uremia.

Fig. 4 shows the development of a rapid and fatal uremia in a goat, with only one kidney, as a result of excessive constriction of the main artery of this kidney.

Renal Function in Hypertensive Sheep and Goats

Constriction of one main renal artery produced no obvious impairment of renal excretory function, as determined only by chemical studies of the blood. No attempt was made to determine urea, creatinine, or other clearances of these animals but there was no accumulation of non-protein nitrogenous substance in the blood.

In animals in which both renal arteries had been constricted moderately, no

chemical changes occurred in the blood to suggest any notable disturbance of renal excretory function. Clearances for the determination of slight disturbance of renal excretory function were not attempted in these animals.

When both renal arteries (Fig. 8, goat 1), or the main artery of the only kidney (Fig. 4, goat 3) were constricted to excess, hypertension resulted, but it was accompanied by progressive uremia which proved fatal.

AUTOPSY RESULTS

In those animals that had persistent hypertension, without significant disturbance of renal excretory function, as indicated only by chemical studies of the blood, (the "benign" phase), no significant gross or microscopic changes were observed in the aorta or large arteries, or in the smaller arteries and arterioles in any organs of the body. The only pathological changes of any kind observed in these animals were located in the kidney. These consisted of parenchymatous degeneration, atrophy, and interstitial lymphocytic infiltration and fibrosis, and were directly dependent upon the degree of constriction of the main renal artery. Even in the kidneys of some of the animals in the benign phase of hypertension there was no significant alteration except slight parenchymatous degeneration.

In those animals that died in uremia, with hypertension, (the "malignant" phase), the same gross and microscopic changes which occur in dogs (11) and other animals also occurred in the sheep and goats. As in other animals, necrosis and fibrinoid degeneration of arterioles and necrotizing arteriolitis appeared in various organs, especially in the gastro-intestinal tract, but not in the kidneys and lungs. These changes do not constitute simple arterio- or arteriosclerosis. They are terminal lesions of a special type and should not be confused with this condition. In our experience with both dogs and other animals these changes have not occurred in animals with hypertension that did not have significant disturbance of renal excretory function, at least terminally. The only changes observed in the kidneys involved the parenchyma and varied from severe diffuse degeneration to diffuse necrosis which depended upon the degree of ischemia.

Physiological Studies of the Humoral Mechanism of Experimental Renal Hypertension in Sheep and Goat

It was determined that both normal and hypertensive sheep and goats respond with a considerable elevation of blood pressure to an intravenous injection of heterologous renin (hog), of homologous renin or of angiotonin (hypertensin) prepared from hog renin and bovine serum globulin (preangiotonin, prehypertensin), the response increasing with but not being directly proportional to the amount injected. The resultant curves of the blood pressure were similar to those which result from the injection of the same substances into

dogs, cats, or rabbits. As in unanesthetized dogs, renin, in a large or small dose, caused a rise of blood pressure which reached its maximum in 3 minutes, or less, and then dropped slowly, but usually persisted at a level higher than normal for 15 minutes or longer. As in unanesthetized dogs, the maximum rise of blood pressure as a result of an intravenous injection of a large or small dose of angiotonin (hypertensin) occurred precipitously, reached its maximum in about 1 minute, and usually returned to normal in about 3 minutes or less. Sheep and goat serum globulin (preangiotonin or prehypertensin) reacted with heterologous (hog) or homologous renin "*in vitro*" to produce angiotonin (hypertensin), which is non-specific, and caused vasoconstriction in the L wen-Trendelenburg toad preparation (12) or raised the blood pressure in the characteristic manner when injected intravenously into normal sheep and goats, as well as dogs and cats.

SUMMARY

Persistent hypertension has been produced in the goat and sheep by constriction of the main renal arteries. The presence or absence of accompanying uremia depends upon the degree of constriction of the renal arteries.

In both sheep and goat, constriction of one main renal artery also caused elevation of the blood pressure which tended to persist longer than in the dog. Excision of the one kidney with main renal artery constricted resulted in a prompt (24 hours) return of the blood pressure to normal.

In the animals with hypertension of long duration but without renal excretory insufficiency, (the "benign" phase) no significant arterio- or arteriosclerosis developed as a result of the hypertension alone. In the animals that had both hypertension and renal excretory insufficiency, (the "malignant" phase) the typical terminal arteriolar lesions developed in many organs. These lesions consisted of necrosis and fibrinoid degeneration of arterioles and necrotizing arteriolitis which should not be confused with arteriosclerosis.

The same humoral mechanism which is responsible for experimental renal hypertension in the dog and other animals also obtains in the pathogenesis of experimental renal hypertension in the sheep and goat.

BIBLIOGRAPHY

1. Goldblatt, H., Lynch, J., Hanzal, R. F., and Summerville, W. W., *J. Exp. Med.*, 1934, **59**, 347.
2. Goldblatt, H., *J. Exp. Med.*, 1937, **65**, 671.
3. Pickering, G. W., and Prinzmetal, M., *Clin. Sc.*, 1938, **3**, 357.
4. Wilson, C., and Byrom, F. B., *Lancet*, 1939, **1**, 136.
5. Drury, D. R., *J. Exp. Med.*, 1939, **68**, 693.
6. Kempf, G. F., and Page, I. H., *J. Lab. and Clin. Med.*, 1942, **27**, 1192.

7. Goldblatt, H., *Am. J. Clin. Path.*, 1940, **10**, 40.
8. Page, I. H., *Science*, 1939, **89**, 273.
9. Lewis, H. A., and Goldblatt, H., *Bull. New York Acad. Med.*, 1942, **18**, 459.
10. Goldblatt, H., *Ann. Int. Med.*, 1937, **11**, 69.
11. Goldblatt, H., *J. Exp. Med.*, 1938, **67**, 809.
12. Fasciolo, J. C., Houssay, B. A., and Taquini, A. C., *J. Physiol.*, 1938, **94**, 281.